

A supplement to

Ophthalmology Times[®]

EUROPE

June 2007

AN ADVANSTAR PUBLICATION

CO-MICS: the future is small

Highlights from an expert roundtable meeting
discussion on coaxial microincision cataract surgery

24 February 2007, the Sacher Hotel, Vienna, Austria


oertli
SWITZERLAND

CO-MICS: the future is small

Highlights from a roundtable discussion on coaxial microincision cataract surgery

Introduction

Cataract surgery has come a long way since ancient Babylonians were using sharp instruments to shove aside cloudy lenses. Time and experience have yielded safer, less painful and more effective methods of addressing cataracts; yet, despite forty years passing since the current industry standard — phacoemulsification — was first introduced, the operation continues to undergo significant tweaking.

In 2005, bimanual microincisional cataract surgery received a hopeful reception from the industry, as surgeons welcomed the advantages promised by smaller wounds. It did not take long, though, for some surgeons to conclude that smallness does not always compensate for sleeveless and two hands are not necessarily better than one. For many, the search for best practice continues.

Perhaps it is to be found in newly-introduced instrumentation designed to accomplish safe, sleeved, coaxial microincision surgery. In a bid to address the needs of these cataract surgeons, Oertli Instruments, a Swiss designer and manufacturer of equipment and instruments for ophthalmic microsurgery, introduced its coaxial microincision cataract surgery (CO-MICS) last December. The unique properties of these new instruments allow surgeons to perform coaxial cataract surgery through incisions of between 1.6 to 1.8 mm for the first time.

As CO-MICS has now been on the market for several months, a meeting was recently convened during which experts were invited to share their experiences in a roundtable discussion. Meeting in Vienna's historic Sacher Hotel, the participants spoke frankly about CO-MICS: its strengths, its limitations, and what potential users should know. Some of the highlights that emerged from the roundtable meeting now follow.

Ophthalmology Times Europe (OTE): Welcome to all of you. Let's begin by discussing your initial motivation for learning about CO-MICS. Professor Menapace, I understand that your primary interests were on the clinical side — a clear corneal incision that is astigmatically neutral and resistant to mechanical deformation. Is this correct?

Dr Menapace: This is correct. From earlier investigations I concluded that coaxial phaco through a posterior limbal incision offers the best results with regard to wound deformation stability and corneal shape stability, so I have been favouring it over clear corneal surgery. With the availability of microcoaxial technology I was motivated to go back into the clear cornea as it offers cosmetically appealing blood-free cataract surgery while providing sufficient wound and corneal stability. Bimanual phaco surgery has several inherent disadvantages; incision oarlocking and chamber instability being the most serious ones. Therefore, I have been favouring microcoaxial over bimanual clear corneal surgery.

OTE: Let's ask the other experts.

Dr Breyer: Perhaps I should first explain how I usually perform cataract surgery. Before surgery, I conduct a video keratometry on every patient, to accurately assess the corneal astigmatism, because I want to correct the astigmatism in every cataract patient: I perform this antiastigmatic surgery sitting at the twelve o'clock position, using my right and left hands for phaco. I was very interested in CO-MICS for special indications rather than routine surgery: a smaller incision is preferable for peripheral corneal degeneration, and, in cases of glaucoma, I can go further into the cornea

Ophthalmology Times EUROPE

Publisher
Dean Graimes
dgraimes@advanstar.com
Tel: +44 (0)1244 393 408

Editorial Director
David Hills
dhills@advanstar.com
Tel: +44 (0)1244 393 256

Editor
Fedra Pavlou
fpavlou@advanstar.com
Tel: +44 (0)1244 393 420

Assistant Editor
Amelia Tope
atope@advanstar.com
Tel: +44 (0)1244 393 153

Sales Manager
Neil Hanley
nhanley@advanstar.com
Tel: +44 (0)1244 393 114

Production Director
Jo Armstrong
Graphic Designer
Amy Munro

Marketing Manager
Helen Taylor
htaylor@advanstar.com

Circulation Manager
Tracey Nicholls

Managing Director
Helen Gardner
Advanstar House,
Park West, Sealand Road,
Chester CH1 4RN, UK
Tel. +44 (0)1244 378 888
Fax +44 (0)1244 370 011

The Panel



PROF DR ANDRÉ DOSSO
Professor, Hôpital Cantonal et
Universitaire, Clinique
d'Ophthalmologie
Geneva, Switzerland



PROF DR CHRISTIAN PRÜNTE
Professor of Ophthalmology &
Optometry
Medical University of Vienna
Austria



DR DETLEV BREYER
Owner & Surgeon, ZeitzBreyer-
Augenheilkunde an den
Schadow Arkaden
Düsseldorf, Germany



DR GIOVANNI B. MARCON
Director Struttura Complessa di Oculistica
Ospedale di Monfalcone
Monfalcone (GO), Italy



PROF DR RUPERT MENAPACE
Professor of Ophthalmology
Medical University of Vienna
Vienna General Hospital
Austria

Disclaimer
The views and opinions expressed in this supplement are those of the physicians and do not necessarily reflect the views and opinions of Advanstar Communications Inc., publisher of Ophthalmology Times Europe, or Oertli Instruments.

Copyright 2007. Advanstar Communications (UK) Ltd. All rights reserved.

No part of this publication may be reproduced in any material form (including photocopying or storing it in any medium by electronic means and whether or not transiently or incidentally to some other use of this publication) without the written permission of the copyright owner except in accordance with the provisions of the Copyright, Designs & Patents Act (UK) 1988 or under the terms of a licence issued by the Copyright Licensing Agency, 90 Tottenham Court Road, London W1P 0LP, UK. Ophthalmology Times Europe (ISSN 1753-3066) and the logo appearing on the cover of this magazine are registered trademarks of Advanstar Communications Inc. Applications for the copyright owner's permission to reproduce any part of this publication should be forwarded in writing to Permissions Dept, Advanstar Communications (UK) Ltd, Advanstar House, Park West, Sealand Road, Chester CH1 4RN, UK. Warning: The doing of an unauthorized act in relation to a copyright work may result in both a civil claim for damages and criminal prosecution.

without hurting the conjunctiva for subsequent penetrating surgery.

As a vitreoretinal surgeon I was especially interested in using CO-MICS for combined surgery because I perform anterior vitrectomy using a cotton swab with a thorough indentation to see the pars plana. With CO-MICS, I can make a stable and watertight 1.6 mm incision before vitrectomy.

Deformation stability is also particularly important in high myopes; those eyes can be less stable, and the wound tightness is worse than in emmetropic eyes. Furthermore, as we involve more bitoric and multifocal IOLs, it is essential that we have an astigmatism neutral incision.

Dr Dosso: I previously tried bimanual microincision but was not happy with it and stopped. When the CO-MICS tips became available, I was interested because a small incision creates no astigmatism issues. Another factor is wound tightness; we know that with corneal incisions, a tight wound lessens the risk of infection.

Dr Marcon: There is definitely a trend towards making incisions smaller in cataract surgery. I've heard other surgeons say that CO-MICS is very important; every surgeon wants to perform cataract surgery through smaller incisions. In Italy, most surgeons perform cataract surgery with a clear corneal surgery approach, which is one of the reasons that a smaller incision is a very good thing.

Dr Prünte: First of all, my motivation was definitely the deformation stability as I often perform 23-gauge vitrectomy, for which I must depress the sclera for anterior retinal surgery (**Figure 1**). My second motivation was for use in astigmatism neutral surgery, because I prefer to perform my surgery from a twelve o'clock position. And then of course, through performing CO-MICS surgery, we found that there are more advantages, which we can discuss later.

OTE: It seems you all agree that cataract surgery benefits from smaller incision size. What technique were you using before you encountered CO-MICS?

Dr Marcon: I was performing a lot of bimanual cataract surgery two or three years ago, but I have since practically abandoned it. It was a difficult technique, often resulting in an unstable anterior chamber. I no longer perform bimanual except for in some cases, such as prior to performing a vitrectomy — although that was before CO-MICS came to the market.

Dr Menapace: My current standard technique is 20-gauge coaxial phaco. I also investigated bimanual phaco two to three years ago, but I abandoned it as well. I moved back to the posterior limbal incision, but ultimately I wanted to get back into the clear cornea

with an incision small enough to guarantee adequate wound and corneal stability. CO-MICS offered me the possibility of further reducing the diameter of the 20-gauge and to exploit the positive impact of small-diameter tips on the fluidics.

Dr Breyer: I routinely use a 2.6 mm incision size. A few years ago I learned about bimanual MICS and could not share the immediate enthusiasm for this method, despite being part of the development team. I used it no more than 20 times: the two instruments are bound tight in the incision and stretch the cornea in such a way that the wound edges don't recover. As a result, I didn't like the appearance of the eyes the next day. There is much greater flexibility with sleeved coaxial phaco. So, I never changed to bimanual MICS; I stayed with 2.6 mm incisions.

I feel that CO-MICS is important in special cases, but a minor drawback of CO-MICS is the surgical time. Standard cataract surgery can be performed in four or five minutes; with CO-MICS it can take seven or eight minutes because of the smaller diameter.

Dr Dosso: With half of my patients I use standard cataract surgery, through 2.6 mm incisions, and for half my patients I use CO-MICS. However, I enlarge the incision to 2 mm for lens implantation. I tried it through a 1.8 mm incision but the tunnel was damaged. The tightness is too great, so I enlarge the wound to 2 mm to use an appropriate lens. Then, with this type of lens there is a risk of shrinkage, so the rhexis is larger with the lenses I'm using. Ultimately, with the larger diameter, there is not much difference between the two techniques.

Dr Prünte: I was never comfortable with the bimanual MICS procedure because it reduced anterior chamber stability and increased non-directed turbulences in the anterior chamber, so it was never a routine procedure for me. Now, my standard is 20-gauge phaco for posterior limbal corneal incisions and I use CO-MICS for combined surgeries. I enlarge the main incision for the implantation of the lens at the end of the vitrectomy procedure, when I am essentially finished, before fluid-air/gas exchange or silicone oil implantation. There is further potential for CO-MICS, but IOLs that can be implanted through smaller incisions and provide the same performance as the IOLs we are using today must become available.

OTE: Let's come back to the sleeveless bimanual cataract surgery. What do you see as the future of this technique? What could be changed about the technique to make it a standard in the future, or is there a future for bimanual?

Dr Prünte: I don't think so; I abandoned it totally

With the availability of microcoaxial technology I was motivated to go back into the clear cornea as it offers cosmetically appealing blood-free cataract surgery while providing sufficient wound and corneal stability

To become the standard procedure, it will take time as we need small incision lenses at our disposal; by then CO-MICS will be ready to expand into routine application

because I couldn't get rid of the anterior chamber stability problem and the turbulence problem. For me it is not practical, as irrigation and suction are in different directions. This turbulence problem is one we will not be able to get rid of.

Dr Marcon: Bimanual taught me a great deal about the fluidics inside the eye; that is an advantage of this technique. But I don't see a future for it, particularly as CO-MICS offers the same advantages without the disadvantages of the technique. I feel that unless the market introduces IOLs with a 1.2 mm or 1.3 mm diameter — and I don't think this will happen in the near future — I don't see a future for the sleeveless bimanual technique. Nearly every surgeon has abandoned it in my country.

OTE: You don't think the problems could be solved from a technical or surgical point of view?

Dr Menapace: The principal problem is that, with no sleeve sealing the incisions, there is either tissue damage when using a tight incision, or chamber instability resulting from variable leakage when using a wider incision. With the limited inflow, surge is always imminent. With these and other problems, and with the advent of concurring microcoaxial systems, the future for sleeveless bimanual phaco becomes less promising.

OTE: When it comes to patient selection, who comes to mind? Which patients would be best treated by CO-MICS?

Dr Prünte: In my experience, CO-MICS is somewhat less effective than 20-gauge phacoemulsification, obviously because of the reduced diameter. This results in a rather longer surgical procedure, which is especially pronounced in extremely hard nuclei. Other than that, it can be used for every type of surgery. It is extremely helpful in small pupils; not only do you have better visibility of the nucleus because of the smaller instruments, but it also has very nice directed fluidics.

OTE: Are there other patients you would prefer to treat with CO-MICS?

Dr Menapace: Combined procedures, whether with filtering surgery or vitrectomy, and patients with rheumatic polyarthritis or corneal surface problems.

Dr Dosso: And in compromised corneas.

OTE: Let's discuss the phaco power; have any of you changed phaco power?

Dr Marcon: I did change the phaco power, but I found that I had more time in position three than before. With standard phaco I tried to aspirate the pieces of the nuclear head first, then the diameter a little bit, and then I was able to aspirate the pieces. With CO-MICS, more power is needed to emulsify, because of the reduced size of the tip. For this reason, I allow some time for my phaco power to be more efficient during phacoemulsification.

OTE: So you didn't change the power parameter in the pulse mode?

Dr Marcon: Yes, I did go back to continuous. That could be a good idea for CO-MICS.

OTE: Are there any other thoughts concerning phaco power?

Dr Prünte: I didn't change my phaco power because my setting is fairly high anyway as I operate it via the foot pedal. But, it is certainly true that phaco time is increased when performing the CO-MICS procedure.

Dr Menapace: I have tried out both pulse mode and continuous mode, and I found continuous to be much more effective with CO-MICS.

Dr Dosso: I also use continuous.

OTE: Professor Menapace, you mentioned that the total phaco time, which is shown on the machine, increases. Does this mean that you have brought more energy into the eye?

Dr Menapace: Of course, yes, it is raised. My phaco time is approximately eight to nine seconds with CO-MICS, but I have even less phaco time with normal phaco or bimanual phaco because of the pulse mode. However, I don't think raising the energy transferred inside the eye is a great issue.

Dr Prünte: From a physical point you apply more energy, but the question is whether this is biologically relevant or not. I am not a physicist, but perhaps this power is better delivered to our target, to the nucleus — perhaps even reducing side effects. This is speculation at the moment, but it would be worth investigating this further.

Dr Marcon: Yes, and I use more power but I use less BSS, so there is less water inside the eye. Perhaps this could be the safest phase? My mean use is 125 cc for

What is CO-MICS?

Coaxial Microincision Cataract Surgery (CO-MICS) instrumentation from Oertli Instruments is a relatively new development that aims to replace traditional phacoemulsification as the standard in cataract operations. CO-MICS allows the removal of cataracts of all grades through incisions no larger than 1.6 – 1.8 mm. The approach maintains the strengths of traditional phaco (such as its low intra- and postoperative complication rate and tendency not to induce astigmatism nor excessively reduce

endothelial cells), while the smaller incision of CO-MICS offers additional benefits for doctors and patients alike.

After their release in December 2006, CO-MICS single use tips, which must be used in conjunction with Oertli instrumentation, are now available globally (except in the US). Oertli Instruments is currently developing a reusable tip for the Indian and Chinese markets, which should be available soon. Tests for these tips are currently being conducted with surgeons in India.

Despite being such a new product, CO-MICS tips are already being used by around 40 surgeons in Europe and India — primarily in a trial capacity. This means that CO-MICS has been used successfully in more than 1,000 surgical procedures. The company expects a further surge in demand as soon as 1.6 mm lenses become established on the market.

According to surgeons who are already employing CO-MICS, the benefits — such as snug-fitting sleeves, negligible-to-no wound

leakage, and improved visibility when operating on small pupils — are numerous and significant. As the doctors involved in this roundtable discussion agree, the learning curve is minimal and new surgeons will have relatively few adjustments to make. An application note ('Coaxial Microincision Cataract Surgery (CO-MICS): the art of mastering the small') is available from the Oertli website (www.oertli-instruments.com) to guide prospective users through a demonstration of CO-MICS.

each operation, which is less than with standard phaco.

Dr Menapace: The higher power reading on the display does not necessarily mean that we raise the risk of tissue damage because the tips may have different characteristics of dispersing this energy within the anterior chamber. I agree that this is a point for further investigation.

Dr Dosso: I have recently begun a study comparing standard surgery with CO-MICS. I have found that even if phaco time is more important, endothelial cell loss is the same with both techniques — although I only have one-week of follow-up results. I also performed pachymetry and it is exactly the same in both techniques; there is no more oedema with CO-MICS. Therefore, the phaco diameter is unimportant; the differences are more likely to be related to the fluids in the eye than to the energy of phaco.

OTE: Do your findings mean that a high power setting on the machine is not relevant for the patient?

Dr Dosso: Yes, that seems to be the case.

Dr Menapace: The eyes don't look different the day after surgery. Did you [Dr Dosso] notice any difference?

Dr Dosso: No, not at all.

Dr Menapace: Did you also measure the total consumption of fluid?

Dr Dosso: It is less. I am not sure exactly by how much, but it is a bit less.

Dr Prünte: That is a good parameter for assessing tissue damage also. I agree this would be a good issue for further investigations. It may be that the power is much more directed to the target, to the nucleus, than with a larger diameter.

Dr Menapace: The total volume of BSS that runs through the eye during surgery is important, but so too is the turnover per time unit. I once performed a number of phaco procedures with the microscope light turned off while introducing an endolight through the paracentesis, which allowed me to visualize the turbulences in the anterior chamber. It was most impressive to see that when phaco and aspiration were active, showers of emulsified nuclear particles were carried along with the turbulences and bumped against the endothelium. Such bombardment may be much less with a low diameter phaco tip, as turbulences are reduced because of the smaller fluid turnover and better confinement to a smaller orifice.

OTE: Concerning the phacoemulsification and the machine settings, what would you recommend to a young surgeon or a surgeon who is not too familiar with CO-MICS? Would you recommend performing phaco with a small tip?

Dr Menapace: 20-gauge.

OTE: Why 20 gauge? Why not the CO-MICS tip?

Dr Menapace: Because it is currently the best compromise for chamber stability and emulsification efficacy.

OTE: What recommendations would you give to an experienced surgeon who wants to change to CO-MICS, particularly concerning machine settings and emulsification technique?

Dr Dosso: To try the divide-and-conquer technique, and to change the setting just for the aspiration and the

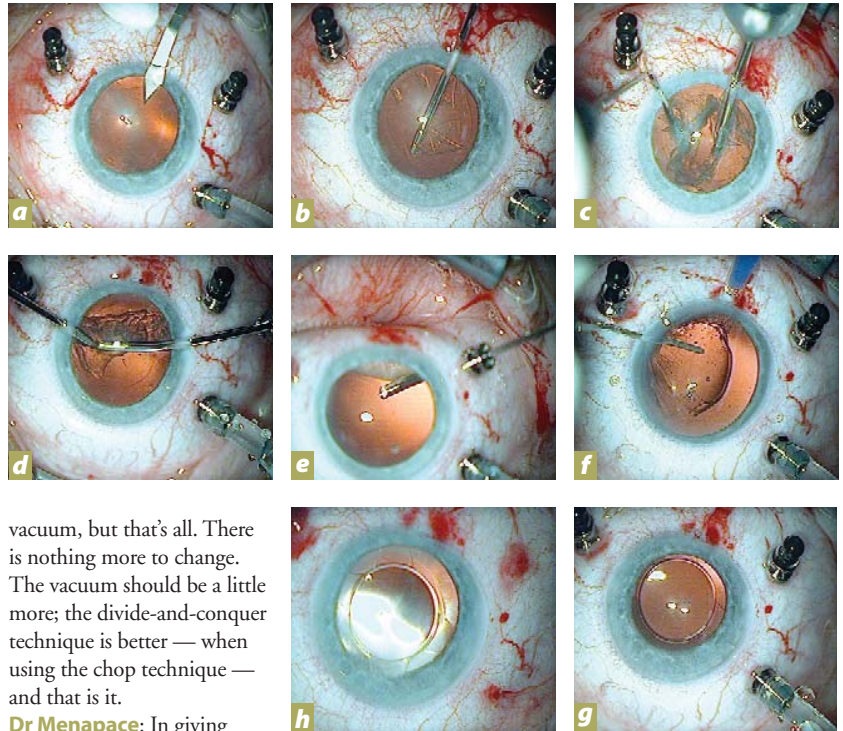


Figure 1: Photographs from a video of a combined CO-MICS and 23G vitrectomy procedure in a patient with epiretinal membrane and macular traction syndrome. After placing the inserts with closed irrigation, a 1.7 mm clear corneal incision (a) is performed. 23G rhexis forceps are used for anterior capsulorhexis (b). Phacoemulsification is most effective combining a divide-and-conquer technique with some aspects of chopping (c). The cortex is removed using a bimanual technique and two paracenteses. (d). The 1.7 mm clear cornea incision is stable, even if extensive indentation pressure is applied during vitrectomy (e). At the end of the vitrectomy procedure, before doing any fluid-air or gas exchange, a microincision IOL is implanted through the original clear cornea incision (f & g). At the end of the procedure the IOL is perfectly centered with the typical fundus appearance after fluid-air exchange (h).

Courtesy of Prof. Dr. Christian Prünte

vacuum, but that's all. There is nothing more to change. The vacuum should be a little more; the divide-and-conquer technique is better — when using the chop technique — and that is it.

Dr Menapace: In giving advice to a surgeon starting with CO-MICS, I would tell him that he should have a look at the graph provided by Oertli that elucidates the dependencies between the flow rate and the unoccluded vacuum (Figure 2). You must reach a certain level of vacuum to get the flow that is displayed on the machine. For example, if he wants to get a flow rate of 20 ml/min, he has to set the vacuum to at least 130 mmHg. He shouldn't go too much above that, otherwise the fluidics may become too aggressive. This, however, is much less critical than with a 19-gauge tip: the smaller the tip diameter, the more it acts as a surge break. I would advise the beginner surgeon to use 200 mmHg or so as a starting point.

OTE: What will he notice if he doesn't raise the vacuum enough?

Dr Menapace: The intended flow will not be reached. It is displayed on the machine but the effective flow will be lower because the pump will be turned off prematurely.

Dr Prünte: It will simply be inefficient.

OTE: Any other experiences to share with surgeons who are new to the procedure?

Dr Menapace: Currently I see a number of good indications that were already mentioned before, but I think the key problem we still have with CO-MICS is that we don't have adequate lenses available. Therefore we have to secondarily enlarge the incision and that limits, for the moment, the general applicability of CO-MICS. However, several developments are underway that will further reduce the incision size required for lens implantation and thus will finally allow us to take full advantage of CO-MICS.

OTE: How long do you think it will be before good lenses small enough for these incisions are on the market?

Dr Menapace: I don't think we will have 1.6 mm

I don't think that we have to find one particular indication for CO-MICS. I think our aim should be to spread this technique to every cataract operation

lenses of a proven lens design and material available in the near future, but there are MICS lenses currently available that can be inserted through 1.8 mm incisions or even less. These are one-piece lenses, however, their long-term postsurgical performance remains to be established.

OTE: Currently there are very few lenses for small incisions available. Does CO-MICS still have advantages? Despite not having the ideal lens, would you still use CO-MICS? And I note you have to enlarge the incision at the end.

Dr Menapace: I would still use CO-MICS for small pupils, combined procedures, and compromised corneas.

Dr Dosso: Corneal transplant, and after a vitrectomy, because after a vitrectomy it is difficult to achieve a stable chamber.

OTE: Let's go to the postoperative findings. What do you see in your patients after the surgery? Do you see any differences, or do you expect any differences for CO-MICS patients when compared with the standard phaco?

Dr Dosso: No, I don't see any change, not a difference.

Dr Menapace: Not as long as we have to enlarge the wound for lens implantation. If the wound can be kept that small, perhaps the surface sensations would be less.

Dr Marcon: Yes, eyes seem very well after the operation. In many ways there is no difference in the eye treated by standard phaco compared with one treated by CO-MICS.

Dr Breyer: You can go back to the clear cornea, resulting in a good cosmetic effect. Consequently, patients don't ring at two o'clock in the morning saying, 'I went to the bathroom and my eye is bleeding, so what shall I do?'

OTE: Have you encountered any corneal burns when you use CO-MICS?

All: No, never.

OTE: Regarding corneal burns, is CO-MICS more risky than other techniques?

Dr Menapace: Possibly less so than with other tips.

OTE: If there were lenses you could implant through the small incisions would you change the postoperative care of the patient? Would you change anything in medication or in care?

Dr Marcon: For the moment, no. But because we enlarge incisions, at the end of the operation it is as if the eye has undergone a standard phaco operation and it is treated like a standard phaco operation. So, I don't know if an incision of 1.6 mm would change my postoperative treatment. It is possible that we could have less inflamed eyes, hence our postoperative treatment approach would change to reflect this, but this is something yet to be demonstrated.

Dr Menapace: Currently I use a cortisone gentamicin mixture as drops for one week, because if the patient should vigorously massage the eye during the first week, the wound might intermittently re-open. It is therefore necessary that the tear film contains an antibiotic so there is a low bacteria count. But if, with a very small incision, it becomes virtually impossible to re-open the incision by digital massage, we could just dispense the antibiotic. Perhaps there would also be less irritation around a smaller wound and thus less need for tear substitutes during the initial period after the operation.

Dr Breyer: If we give eye drops to patients two days in advance and five days after the surgery, within three to four days many people get red eyes and allergies to gentamicin or floxacin. Removing or reducing the need for drops could benefit the patient.

OTE: Would you leave out the medication if you had a 1.6 mm incision?

Dr Menapace: Yes, I would no longer prescribe an antibiotic.

Dr Prünte: I don't currently use antibiotics after 20-gauge surgery. But I am fairly certain the safety margin for the patient would be better with CO-MICS. The risk is minimal to zero that the patient could open the corneal incision just by pressure or massaging, so I would be very confident that it wouldn't be a problem with a small incision.

Dr Marcon: We need more time to see if the rate of infection would be lower with this technique, but we need more patients that have undergone the procedure to understand this issue.

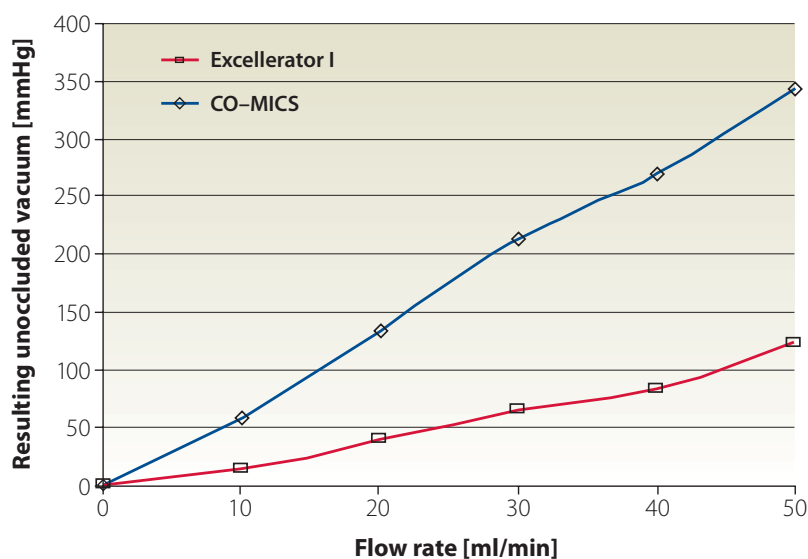
OTE: What is the potential of CO-MICS for the future? In three or four years, will this be the state of the art technique for performing surgeries?

Dr Prünte: I personally believe it has the potential. It has become standard procedure in my hands for special cases, combined procedures, small pupils, and other such cases. The main limitation at the moment is the non-availability of the IOLs. As soon as we have this problem solved, CO-MICS has the potential to be a standard routine procedure.

Dr Dosso: We are all waiting for lenses that demonstrate good results when implanted through small incisions.

Dr Breyer: The standard for phaco surgery is currently 20-gauge; however, I feel that 23-gauge is the best for me at the moment. I do think that CO-MICS is absolutely the right way to go and it will be a successful story. I also believe that the 1.6 mm incision is very helpful already in those special cases we discussed earlier.

Figure 2: Relationship between flow rate and the unoccluded vacuum. When working with the CO-MICS tip, preset vacuum limit values must be increased.



Before there was CO-MICS...

Eye surgeons agree that a good incision should not be vulnerable to digital manipulation, nor should it induce corneal astigmatism. In 2004, Professor Rupert Menapace gave a lecture to The Society of German Ophthalmic Surgeons, 17th Annual Meeting, Nuremberg, Germany, which explored how ultra-small incisions of bimanual MICS compared with the larger incisions of coaxial phaco. He concluded that, although bimanual MICS offered some theoretical benefits, its shortcomings were significant. Now, as CO-MICS promises to surmount those shortcomings, a review of Professor Menapace's presentation was a fitting way to begin the roundtable discussion. What follows is a summary of Professor Menapace's findings.

According to a systematic evaluation of various incision constructions, sizes and locations using analytical software, a 3 mm clear corneal incision (CCI) induces

significant asymmetric sectorial flattening encompassing the pupillary centre (C. Vass & R. Menapace, "Computerized statistical analysis of corneal topography for the evaluation of changes in corneal shape after surgery," *Am. J. Ophthalmol.* 1994;118:177-184). This flattening further increases as the CCI location is rotated superiorly and a deeper pre-cut is made. Conversely, a temporal posterior limbal incision (PLI) can fully preserve the corneal shape within the clinically relevant 3 mm optical zone (OZ) up to a width of 4 mm.

A square wound has been proven to provide sufficient deformation resistance against digital massage, especially when the limbus is incorporated. For standard phaco and IOL surgery, square PLLs provide the best deformation stability and full astigmatic neutrality within the 3 mm OZ. These tests have

demonstrated that bimanual MICS has two major disadvantages:

The rigid phaco tip and infusion cannula distend the slit-shaped paracentesis openings, and cause corneal locking and varying leakage when tilted. For efficient emulsification, increased flow and vacuum settings are required, while influx through the 19- and 20-gauge lumen is insufficient. This reduces chamber stability to a varying extent and increases the propensity for unattended chamber collapse. Tight-fitting small incisions would ease the problem, but reduce visual control by stromal oedema, cause endothelial trauma, and jeopardize the self-sealing wound properties by damaging the corneal lip.

Conventional foldable IOLs still require 2.4 mm incisions for atraumatic insertion. When forced through smaller incisions, the non-elastic corneal incision may be distended or torn at its edges, which again may result in

insufficient self-sealing. Plate-haptic MICS lenses may be inserted through incisions smaller than 2 mm. However, resistance against fibrotic retraction and haptic deformation is reduced, and long-term YAG-laser capsulotomy rates remain to be established.

Microcoaxial phaco can now be performed through incisions as small as 1.6 mm. Unlike standard 3 mm CCIs, these avoid conjunctival bleeding, provide for topographic stability (including the very periphery), and safety (even against pinpoint indentation at the wound entrance). Furthermore, a sleeve fully preserves chamber stability and wound tightness. Currently, phaco incisions must still be widened to accommodate stressless insertion of standard IOLs; however, advances in IOL technology will soon catch up with the new standards set by microcoaxial phaco.

OTE: What would be your advice to someone interested in practicing smaller incision surgery?

Dr Menapace: I would tell him that, if they are already performing 20-gauge surgery, there is no need to change the technique. He has to know to adjust the vacuum and the flow of the machine, and then he will become more comfortable with this technique; learning the advantages and indications for which he can best use this technique. To become the standard procedure, it will take time as we need small incision lenses at our disposal; by then CO-MICS will be ready to expand into routine application.

OTE: So a benefit for the surgeon is that it is a safer system from a fluidics point of view. What about the patient? Why should a patient choose to have surgery with smaller incisions?

Dr Menapace: One reason is that the surgeon can use a smaller incision, allowing him to go into the clear cornea — which avoids bleeding and may reduce irritation. There may also be less need for topical medications.

Dr Prünte: Less irritation, better safety margin, less risk if unwanted mechanical pressure is applied to the eye after surgery.

OTE: Any other advice we could give to surgeons interested in this technology?

Dr Prünte: My learning experiences were related primarily to vacuum setting, so my advice would be not to be too cautious in increasing your vacuum. The fluidics are so stable that you really can increase it.

Dr Marcon: I don't think that we have to find one particular indication for CO-MICS. I think our aim should be to spread this technique to every cataract

operation. Of course, at the beginning we will use it in simple cases, as we learn the technique. But I think our goal is to try to use this technique in every cataract operation.

OTE: Thank you for this very interesting discussion. I think we have covered what we know about CO-MICS today quite well. I would summarize the main points of our discussion as follows:

- **CO-MICS works well.**
- **It is already now recommended for special indications.**
- **It is safe.**
- **It has a short learning curve.**

The future depends entirely on whether there will be implants available to fit through 1.6 mm and 1.8 mm incisions. Of course, the more surgeons that are using this tip and this technique, the sooner it will mature and the more indications will be found. Whether 20-gauge will remain the optimum, we don't know — it might well be the case, but CO-MICS does have several important uses now and great potential for the future. I really look forward to seeing how this technique progresses. Thank you very much for this fruitful discussion.

A note from the sponsor

I think we are much more advanced than we were two years ago when we were focused on the bimanual technique. We hope that Oertli has made a contribution to patient satisfaction, surgeon benefit and to the industry as well.

Andreas Bosshard,
President, Oertli Instruments

