

EUROPEAN OPHTHALMIC REVIEW

VOLUME 6 • ISSUE 1 • SPRING 2012 • EXTRACT

**Long-term Results of a Novel
Minimally Invasive High-
frequency Deep Sclerotomy
Ab Interno Surgical Procedure
for Glaucoma**

Bojan Pajic,^{1,2,3} Brigitte Pajic-
Eggspuehler,¹ Ivan Haefliger¹ and
Farhad Hafezi²

*1. Swiss Eye Research Foundation, Eye Clinic
ORASIS, Titlisstrasse 44, Reinach; 2. Division
of Ophthalmology, Department of Clinical
Neurosciences, University Hospitals of
Geneva; 3. Eye Hospital VIDAR-ORASIS Swiss,
University of Novi Sad, Faculty of Physics,
Novi Sad*

In a Class of its Own

faros™ anterior

Phaco of complete perfection
and the highest efficiency.

faros™ with Oertli **easyPhaco®**
gives you both.

faros™ with Oertli **easyPhaco®** –
anyone who has tried it once will
never want to part with it.



Long-term Results of a Novel Minimally Invasive High-frequency Deep Sclerotomy *Ab Interno* Surgical Procedure for Glaucoma

Bojan Pajic,^{1,2,3} Brigitte Pajic-Eggspuehler,¹ Ivan Haefliger¹ and Farhad Hafezi²

1. Swiss Eye Research Foundation, Eye Clinic ORASIS, Titlisstrasse 44, Reinach; 2. Division of Ophthalmology, Department of Clinical Neurosciences, University Hospitals of Geneva; 3. Eye Hospital VIDAR-ORASIS Swiss, University of Novi Sad, Faculty of Physics, Novi Sad

Abstract

High-frequency deep sclerotomy (HFDS) glaucoma surgery is a new *ab interno* procedure to lower the intraocular pressure in open-angle glaucoma. Using high-frequency energy, six small pockets are formed which significantly reduce the outflow resistance for aqueous humour. This article presents the impressive results of a long-term study about the HFDS glaucoma procedure and demonstrates its efficacy and safety. The operation technique and the devices used for a successful HFDS glaucoma intervention are described step by step.

Keywords

Open-angle glaucoma, high-frequency deep sclerotomy (HFDS), abee® Glaucoma Tip, minimally invasive, intraocular pressure, surgical procedure, diathermy probe

Disclosure: The authors have no conflicts of interest to declare.

Received: 3 January 2012 **Accepted:** 18 January 2012 **Citation:** *European Ophthalmic Review*, 2012;6(1):17–20

Correspondence: Bojan Pajic, Medical Director, Orasis Eye Clinic, Titlisstrasse 44, 5734 Reinach, Switzerland. E: bpajic@datacomm.ch

Support: The publication of this article was funded by Oertli Instruments.

Purpose

The aim of this study was to demonstrate the efficacy and safety of a new surgical procedure termed high-frequency deep sclerotomy *ab interno* (HFDS) (formerly STT) for the treatment of primary open-angle glaucoma and juvenile glaucoma.

Patients and Methods

The main inclusion criterion for this study was an insufficient response to medical treatment of intraocular pressure (IOP). Data were documented according to a prospective study protocol. Fifty-three HFDS procedures *ab interno* in 53 patients with primary open-angle glaucoma and five with juvenile glaucoma were carried out between 1 April 2002 and 31 July 2002.

High-frequency Diathermic Probe

The high-frequency diathermic probe (abee® Glaucoma Tip, Oertli Instrumente AG) consists of an inner platinum electrode, which is isolated from the outer coaxial electrode. The platinum probe tip is 1 mm in length, 0.3 mm high and 0.6 mm wide and is bent posteriorly at an angle of 15° (see *Figures 1*). The external diameter of the probe measures 0.9 mm. Modulated 500 kHz current generates a temperature of approximately 130°C at the tip of the probe. The set-up provides high-frequency power dissipation in the close vicinity of the tip. As a result, heating of tissue is locally very limited and is applied as a rotational ellipsoid.

Surgical Procedure

A clear corneal incision (1.2 mm wide) was placed in the temporal upper quadrant using a diamond knife. A second corneal incision

was performed 120° apart from the first, followed by injection of Healon GV®. The high-frequency diathermic probe (abee Glaucoma Tip) was inserted through the temporal corneal incision. Visual inspection of the target zone (opposite the iridocorneal angle) was observed by a four-mirror gonioscopy lens. The high-frequency tip penetrates up to 1 mm nasally into the sclera through the trabecular meshwork and Schlemm's canal (see *Figure 2*), forming a deep sclerotomy (i.e. 'pockets') 0.3 mm high and 0.6 mm wide (see *Figure 3*). This procedure was repeated four times within one quadrant. Healon GV was evacuated from the anterior chamber with bimanual irrigation/aspiration.

Results

The mean age of patients with open-angle glaucoma was 72.3 ± 12.3 years (range 15–92 years). Seventeen patients (32 %) were female and 36 patients (68 %) male. The mean age of patients with juvenile glaucoma was 9 ± 1.4 years (range 7–11 years). One patient (20 %) was female and four patients (80 %) male. In 25 cases (47.4 %) of open-angle glaucoma the right eye, and in 28 cases (52.6 %) the left eye, was treated. In three cases (60 %) of juvenile glaucoma the right eye, and in two cases (40 %) the left eye, was treated. Decimalised Snellen visual acuity was 0.7 ± 0.3 (range 0.1–1.0) for open-angle glaucoma and 0.58 ± 0.3 (range 0.1–0.8) for juvenile glaucoma, pre-operatively. For all patients the follow-up was 72 months.

Mean pre-operative IOP in the study population of 53 patients with primary open-angle glaucoma was 25.6 ± 2.3 mmHg (range 18–48 mmHg) and in the study population of five patients with juvenile glaucoma was 39.6 ± 2.3 mmHg (range 34–46 mmHg). Mean IOP after

Figure 1: abee® Glaucoma Tip




Figure 3: Thalamus 0.3 mm High and 0.6 mm Wide

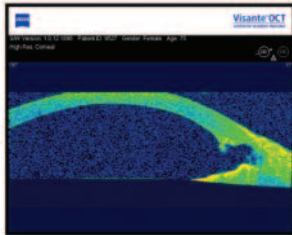


Figure 5: Juvenile Glaucoma Average Level of Intraocular Pressure

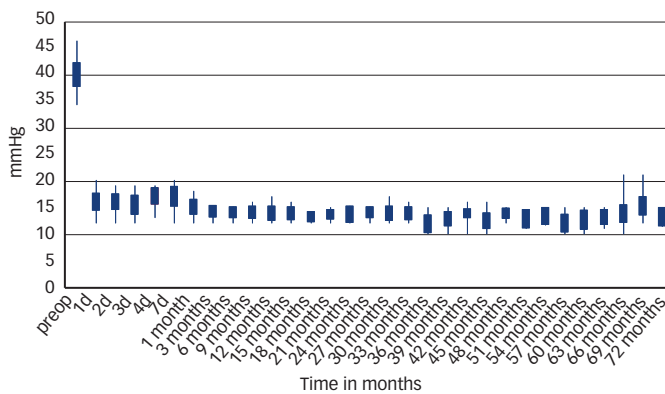
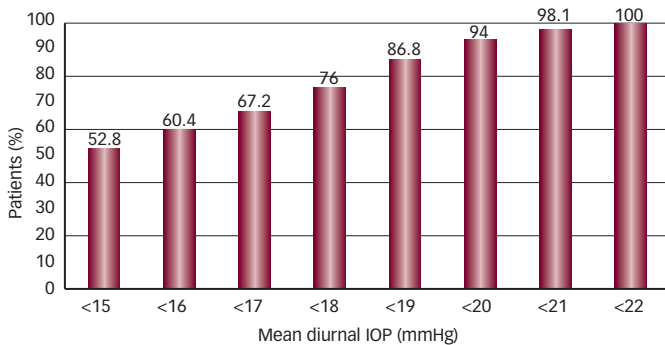


Figure 6: Primary Open-angle Glaucoma Percentage of Patients Reaching Specified Intraocular Pressure Levels



IOP = intraocular pressure.

72 months was 14.7 ± 1.8 mmHg (range 10–21 mmHg) for primary open-angle glaucoma and 13.2 ± 1.3 mmHg (range 12–15 mmHg) for juvenile glaucoma. The IOP drop for both groups was statistically highly significant ($p < 0.001$) at all measured post-operative intervals (see Figures 4 and 5). Pressure reduction at any time of standardised follow-up was statistically significant compared with pre-operative data at a level of $\alpha < 0.03$ (Bonferroni-corrected). In the juvenile

Figure 2: Penetration of the High-frequency Tip (A) and Penetration up to 1 mm Nasally into the Sclera (B)

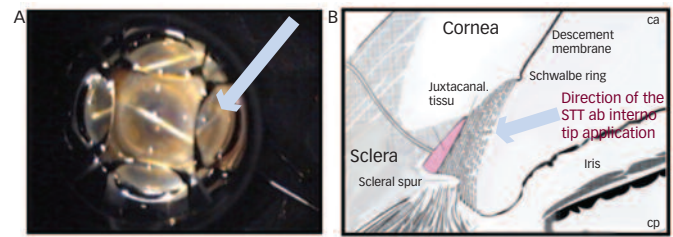


Figure 4: Primary Open-angle Glaucoma Average Level of Intraocular Pressure

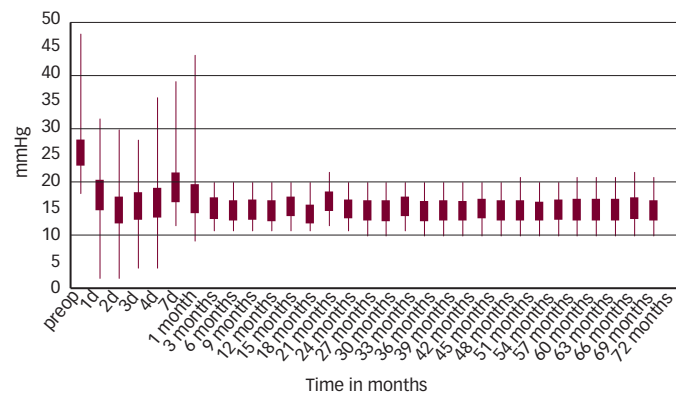
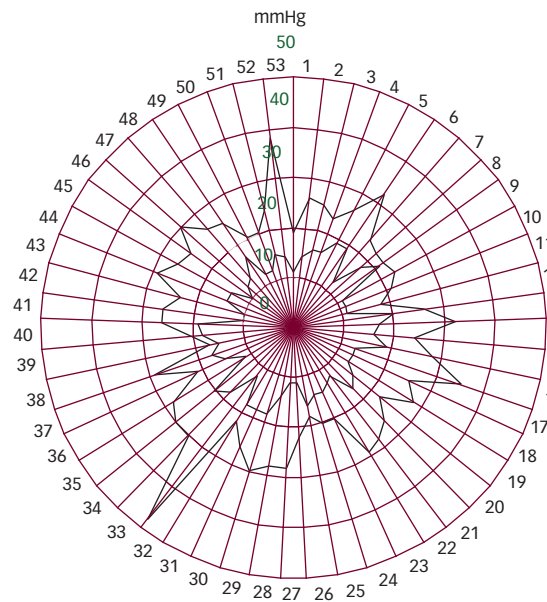


Figure 7: Primary Open-angle Glaucoma Pre-operative and Post-operative Level of Intraocular Pressure after 48 Months of Follow-up



glaucoma group, with five patients there are not enough cases to get conclusive statistics but the results show the tendency.

At month 72 after surgery, 52.8 % of patients with open-angle glaucoma had an IOP <15 mmHg, 76 % had an IOP <18 mmHg and 79.2 % had an IOP <21 mmHg (see Figure 6); 80 % of patients with juvenile glaucoma had an IOP <15 mmHg and 100 % had an IOP <18 mmHg. After 72 months, 84.9 % achieved >20 % reduction in IOP and 77 % of treated patients with open-angle glaucoma achieved

Figure 8: Administration of Pressure-reducing Eye Agents during 72 Months for Group with Primary Open-angle Glaucoma

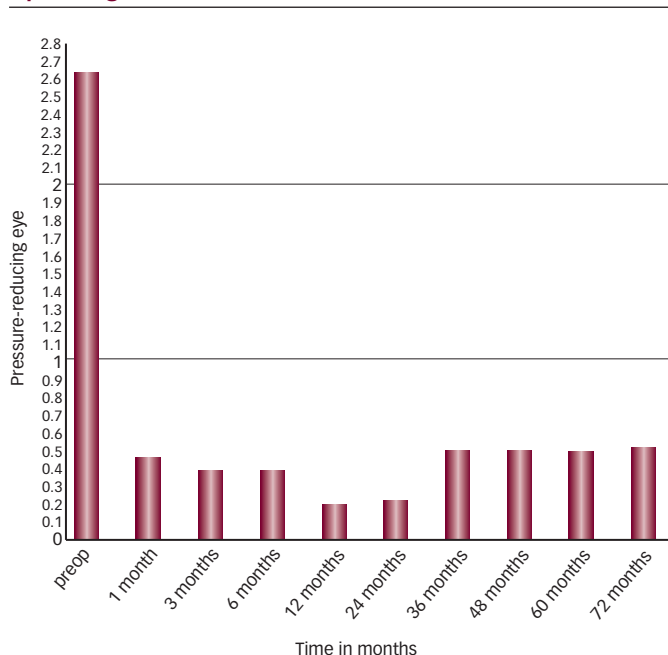
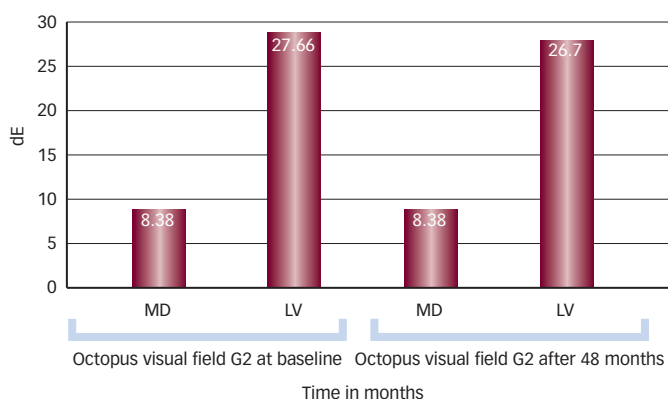


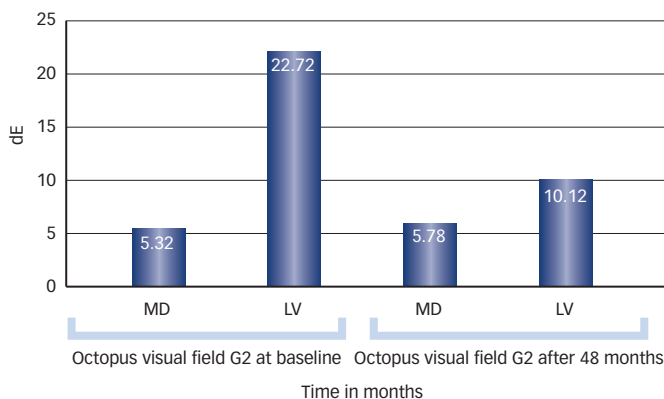
Figure 9: Primary Open-angle Glaucoma Visual Field Analysis



>30 % reduction of IOP. After 72 months, 100 % of treated patients with juvenile glaucoma achieved >30 % reduction of IOP. The complete success rate, defined as an IOP lower than 21 mmHg without medication, was 79.2 % in the open-angle glaucoma group and 80 % in the juvenile glaucoma group at 72 months. The qualified success rate, defined as an IOP lower than 21 mmHg with medication, was 100 % for all patients at 72 months (see Figure 7). After 72 months, it was necessary to administer IOP-reducing medication in 11 eyes (20.8 %) in the open-angle glaucoma group (see Figure 8) and one eye (20 %) in the juvenile glaucoma group. There were no significant changes comparing the visual field for open-angle glaucoma, with mean defect (MD) 8.38 ± 2.44 and loss variance (LV) 27.7 ± 5.11 at baseline and MD 9.03 ± 2.45 and LV 28.2 ± 5.66 ($p=0.29$ for MD, $p=0.37$ for LV) at 72 months (see Figure 9), or for juvenile glaucoma, with MD 8.73 ± 3.12 and LV 28.2 ± 29.45 at baseline and MD 9.9 ± 1.97 and LV 21.3 ± 14.15 ($p=0.56$ for MD, $p=0.72$ for LV) at 72 months (see Figure 10).

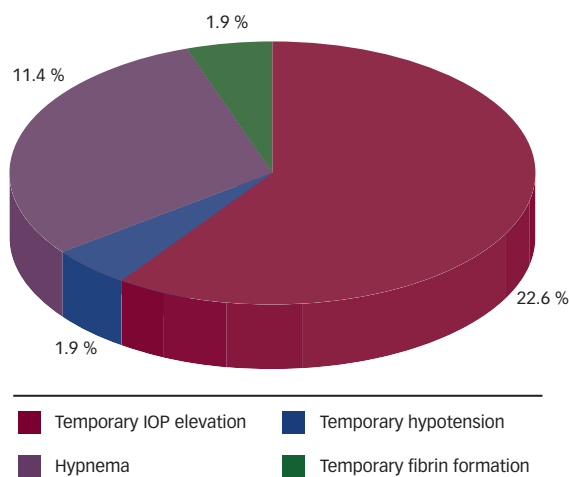
For the five cases with juvenile glaucoma no side effects have been seen up to now. With more cases, complications could be

Figure 10: Juvenile Glaucoma Visual Field Analysis



LV = loss variance; MD = mean defect.

Figure 11: Complications after High-frequency Deep Sclerotomy Ab Interno Surgical Procedure



IOP = intraocular pressure.

visualised, such as the following described for the open-angle glaucoma group. Temporary IOP elevation higher than 21 mmHg was observed in 12 of 53 eyes (22.6 %). These patients responded well to pressure-reducing treatment with Timolol 0.5%, Dorzolamid or Bromonidin and medication could gradually be withdrawn in all of these patients. A single case of hypotension (1.9 %) was observed, that lasted for three days after surgery. Hypnema was present in six cases (11.4 %), which disappeared within the first two weeks after surgery. One eye (1.9 %) exhibited transient fibrin formation. Fibrin was cleared within one day after frequent application of topical dexamethasone (see Figure 11).

Conclusions

HFDS (formerly STT) *ab interno* is a minimally invasive, safe and efficacious surgical technique for lowering IOP in open-angle glaucoma and juvenile glaucoma. Also, the technique avoids stimulation of episcleral and conjunctival tissues as in trabeculectomy and conventional non-penetrating surgery. In this study, diathermy was used to create four thalami and this corresponds to a resorption surface area of 2.4 mm². The number of thalami chosen was arbitrary and seems to provide a sufficient long-term decrease in IOP as well as a low rate of post-operative complications. There is potential for a further IOP drop if six applications are made and we are currently investigating this. ■

The High-frequency Deep Sclerotomy Glaucoma Procedure

Figure 1: Oertli abee® Tip for High-frequency Deep Sclerotomy Glaucoma Procedure



Figure 2: Point of Application

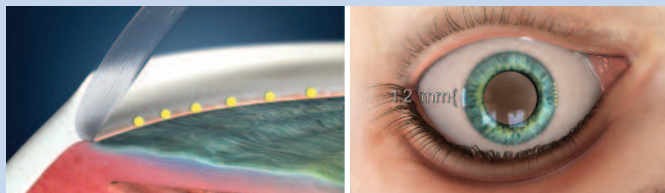


Figure 3: Position of abee® Tip

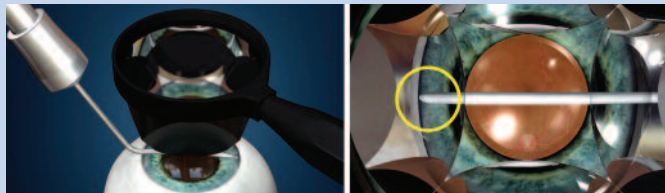
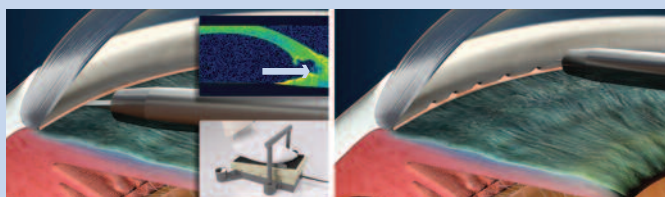


Figure 4: How to Set the Pockets



High-frequency deep sclerotomy (HFDS) glaucoma surgery is a new *ab interno* procedure to lower the intraocular pressure in open-angle glaucoma. Using high-frequency energy, six small pockets are formed which significantly reduce the outflow resistance for aqueous humour. The pockets penetrate through the trabecular meshwork and Schlemm's canal and end in the sclera.

The devices used for HFDS *ab interno* glaucoma surgery are the Oertli abee® glaucoma probe with a specially formed platinum tip. The abee tip, with its handpiece, is connected to an Oertli surgery platform. A four-mirror gonioscopy lens is placed on the cornea to open the view into the iridocorneal angle.

The target point for the application is the iridocorneal angle opposite the incision, normally nasal. However, the probe design also allows access to the lower orbital area.

The minimally invasive HFDS *ab interno* glaucoma procedure is ideal for combined cataract and glaucoma surgery. It is applied after completion of the cataract surgery with the intraocular lens already in place and the pupil narrowed. However, HFDS can easily be performed as a singular procedure. In this case, the use of a high-viscosity viscoelastic is recommended, as well as pupil-narrowing drops (for instance carbachol).

Performing the High-frequency Deep Sclerotomy Procedure

1. The anterior chamber is filled with a viscoelastic substance.
2. Methocel is applied to the cornea.
3. The abee tip probe is inserted through the incision and positioned at the desired point of application.
4. The four-mirror gonioscopy lens is placed on the cornea allowing visualisation of the iridocorneal angle. Do not push on the limbus, to avoid formation of Descemet folds, which could obstruct view into the angle.
5. Place the tip at the level of the trabecular meshwork and simultaneously press the pedal and push the tip of the probe forwards. Do not perforate. After three beeping sounds, release the pedal and retract the abee tip from the pocket.
6. Repeat the procedure and place five more pockets for a total of six close to each other.
7. As with many other surgical glaucoma procedures, HFDS *ab interno* glaucoma surgery may lead to IOP pressure peaks within the first days post-operation. This is an absolutely common phenomenon. Avoid application of pressure-lowering drops because it can slow down the healing process. The eye pressure will reduce itself to the mid-tens mmHg and will continue to drop for a period of six months. However, the following post-operative drug regimen is mandatory: tobramycin/dexamethasone, either as a fixed-dose combination, or separately four times a day for four weeks post-operation, and pilocarpine 2 % eye drops for four weeks.

The HFDS *ab interno* function with abee tip can be installed on any yellow Oertli surgical platform. ■



Saffron House
6-10 Kirby Street
London
EC1N 8TS

EDITORIAL

Tel: +44 (0) 20 7452 5357
Fax: +44 (0) 20 7452 5050

SALES

Tel: +44 (0) 20 7452 5230
Fax: +44 (0) 20 7452 5606

E-mail: info@touchbriefings.com
www.touchbriefings.com