

# High-Frequency Deep Sclerotomy


## A MIGS Procedure for Mild-to-Moderate Glaucoma

By **FLORIAN SUTTER, MD**  
**EYE CLINIC IN HERISAU AND**  
**APPENZEL, SWITZERLAND**

MINIMALLY INVASIVE GLAUCOMA surgery (MIGS) has established itself in the modern glaucoma management algorithm as an option for effectively reducing intraocular pressure (IOP) with advantages of faster recovery and better safety compared to traditional glaucoma surgery. Most MIGS procedures, however, are indicated only to be used in combination with cataract surgery and have a modest IOP-lowering effect that makes them appropriate primarily for treating mild open-angle glaucoma. Within the MIGS category, HFDS® (Oertli Instrumente AG, Switzerland) stands out as an implant-free approach able to be performed by itself or combined with cataract surgery and offering impressive IOP-lowering potential that makes it a viable option for treating mild to moderate glaucoma.

### HFDS® in brief

HFDS, which is an acronym for high-frequency deep sclerotomy, creates a deep sclerotomy in the angle underneath Schwalbe's line and above the scleral spur. It is a minimally invasive, ab interno procedure, that is performed with a high-frequency diathermy handpiece optionally available with all Oertli surgery platforms (Catarhex 3®, Faros™, OS4™). The reusable HFDS glaucoma tip (**Figure 1**) penetrates approximately 1 mm into the sclera, extending through the pigmented trabecular meshwork, Schlemm's canal and into the intrascleral collector channels. Therefore, the depth of the HFDS sclerotomy addresses the highest outflow resistance



**Figure 1.**  
The HFDS glaucoma tip

in the conventional outflow pathway, the pigmented trabecular meshwork.

### Surgical technique

HFDS is a simple and straightforward procedure with a relatively short learning curve that is also accessible to ophthalmic surgeons who are not glaucoma specialists. In my opinion, HFDS is easier to perform than other MIGS procedures since it does not require manipulation and proper positioning of any implant. Eliminating the use of an expensive implant, HFDS also offers a cost advantage. Adverse events after HFDS occur early, are generally mild, and are self-limiting or transient with minimal management. Its early postoperative safety minimises the number of necessary follow-up visits post HFDS. Because it leaves no foreign material in the eye, HFDS might also have a safety benefit long-term. In addition, HFDS can be repeated, and as a conjunctiva-sparing procedure, it does not preclude future penetrating glaucoma surgery.

Performing HFDS does require the use of a direct or indirect gonioscopic lens for intraoperative visualization. Surgeons who are not familiar with this technique can easily acquire the

necessary skill through wet lab training or with a dry lab kit available from Oertli.

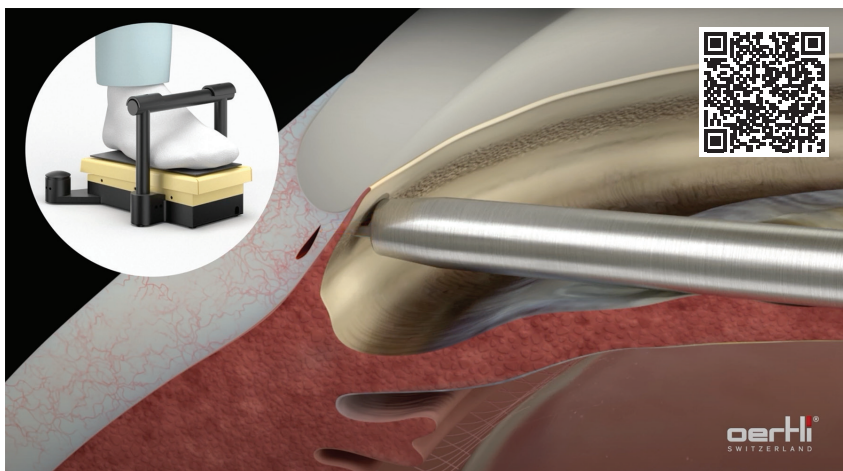
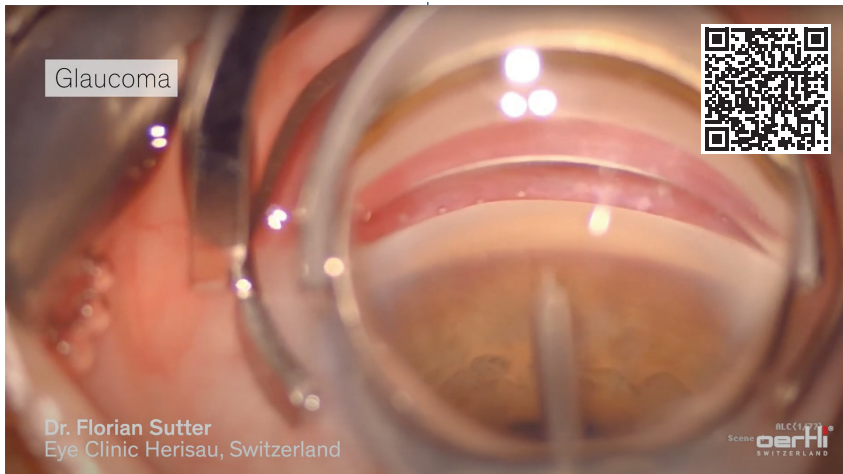
I usually perform HFDS in patients undergoing cataract surgery where it adds just 3 or 4 minutes to the operative time. It is done after completing phacoemulsification and IOL implantation, and whatever anaesthesia was used for the cataract portion usually provides sufficient coverage for HFDS.

The procedure is depicted in a surgical video (**Figure 2**) and online animation.

### Documenting the outcomes

Studies appearing in the peer reviewed literature and results reported in other forums support the conclusion that HFDS is safe and provides effective and durable IOP control.<sup>1-4</sup> Histological findings from HFDS-treated eyes examined postmortem showing that the sclerotomy remains open long-term corresponds with the procedure's clinical longevity.<sup>1</sup>

Pajic et al. published findings from longer-term follow-up of two patient cohorts treated with HFDS.<sup>1,2</sup> One report included 53 eyes followed for 6 years after standalone HFDS done with only four deep sclerotomies.<sup>1</sup>



**Figure 2.** The HFDS glaucoma tip extends through the pigmented trabecular meshwork, Schlemm's canal and into the intrascleral collector channels. Once the tip is properly positioned, the surgical pockets are created by simultaneously depressing the footpedal to position 3 while advancing the tip forward. (Scan QR codes to watch full videos.)

Mean IOP was significantly reduced (42%;  $P < .001$ ) from 25.6 mmHg at baseline to 14.7 mmHg at 6 years; daily medication burden decreased from 2.6 to 0.5. At last follow-up, IOP was  $<15$  mmHg in 53% of patients and  $<20$  mmHg in 94% of patients.

The most common early adverse events were mild temporary IOP elevation (22.6%) that usually responded well to medication, and hyphema that disappeared within 2 weeks (11.5%). Cataract formation in nine eyes (17.1%), including three eyes with no change in visual acuity, was the only late side effect noted.

A second study by Pajic et al. including 49 eyes treated with HFDS

and cataract surgery showed similar benefits for reducing IOP and medication burden at 4 years of follow-up.<sup>2</sup> Surgeons in Egypt reporting data from 43 eyes followed for 9 months after standalone HFDS with six sclerotomies showed IOP was reduced 40% from the 31.4 mmHg baseline and was controlled at  $<21$  mmHg without medication in 91% of eyes.<sup>3</sup> Data from other surgeons following patients for 2 to 3 years after HFDS done in a combined procedure show equally good results.<sup>4</sup>

**Conclusion**

HFDS, is a simple and straightforward, time- and cost-efficient MIGS

procedure that is safe and provides significant, durable IOP reduction. As an appropriate choice for managing patients with moderate as well as mild glaucoma, HFDS has had a significant impact on my surgical management of glaucoma. Before I adopted HFDS, I would perform combined phacoemulsification/MIGS in only about 1 of 50 patients with both cataract and glaucoma because I only offered the combined procedure to individuals with mild glaucoma. Now, I am performing combined surgery in at least 1 in 20 patients because with HFDS I have confidence that I can also provide the benefits of IOP control and reduced medication burden to the larger group of patients with moderate glaucoma.

**REFERENCES**

1. Pajic B, et al. New minimally invasive, deep sclerotomy ab interno surgical procedure for glaucoma, six years of follow-up. *J Glaucoma*. 211;20(2):109-114.
2. Pajic B, et al. High-frequency deep sclerotomy, a minimal invasive ab interno glaucoma procedure combined with cataract surgery: physical properties and clinical outcome. *Appl Sci*. 2020;10(1):218.
3. Abushanab MMI, et al. The efficacy and safety of high-frequency deep sclerotomy in treatment of chronic open-angle glaucoma patients. *Biomed Res Int*. 2019;1850141.
4. Oertli Instruments, data on file.
5. Le C, et al. Surgical outcomes of phacoemulsification followed by iStent implantation versus goniotomy with the Kahook Dual Blade in patients with mild primary open-angle glaucoma with a minimum of 12-month follow-up. *J Glaucoma*. 2019;28(5):411-414.
6. Dorairaj S, et al. Twelve-month outcomes of excisional goniotomy using the Kahook Dual Blade® in eyes with angle-closure glaucoma. *Clin Ophthalmol*. 2019;13:1779-1785.
7. Clement CI, et al. One-year outcomes following implantation of second-generation trabecular micro-bypass stents in conjunction with cataract surgery for various types of glaucoma or ocular hypertension: multicenter, multi-surgeon study. *Clin Ophthalmol*. 2019;13:491-499.
8. Davids AM, et al. Ab interno canaloplasty (ABIC)-12-month results of a new minimally invasive glaucoma surgery (MIGS). *Graefes Arch Clin Exp Ophthalmol*. 2019;257(9):1947-1953.



Dr Sutter is a specialist in ophthalmology and ophthalmic surgery, Eye Clinic in Herisau and Appenzell, Switzerland.

Dr Sutter has no financial interests to disclose.